EFFECT OF NICOTINE ADMINISTRATION AND ITS WITHDRAWAL ON THE REPRODUCTIVE ORGANS, FERTILITY, AND PREGNANCY OUTCOME IN FEMALE RATS.

BY

Manal M. S. El-Meligy; Randa H. Abdel Hady*;
Amal R. Abdel Samaei and Heba M. Saad Eldien**

Departments of Anatomy, Forensic Medicine and Clinical Toxicology and Histology***
Faculty of Medicine, Assiut University

ABSTRACT

There is clear support for an association between smoking and decreased female fertility. Substantial harmful effects of cigarette smoke on fecundity and reproduction have become apparent but not generally appreciated. Therefore the present work studied the effect of nicotine on some reproductive organs and the morphological abnormalities of offsprings of nicotine treated mothers. The animals were divided into two main groups: Group A (non pregnant rats) and group B (pregnant rats).Group A was subdivided into three subgroups: (1) Saline treated control group, (2) Nicotine treated group, that was injected daily with nicotine in a dose of 0.4mg/100. gm body weight which is equivalent to the amount of nicotine passing to the blood of the heavy smoker subcutaneously for 3 weeks, (3) Rehabilitation group that was injected with nicotine in the same previous dose and duration then left for 2 months after stoppage of injection. Group B was subdivided into two subgroups: (1) Control group which was left to get pregnant and injected with 0.9% saline subcutaneously daily from the day 6-20 of pregnancy. (2) Nicotine treated group that was injected with nicotine in the same dose used in group (A) from the day 6-20 of pregnancy. Non pregnant animals of group A 1, 2 were sacrificed at the end of 3 weeks, whereas those of groups A 3 were sacrificed 2 months later. Uterine and ovarian specimens were fixed in 10% formaline solution for histopathological examination. Pregnant rats of group B (1),(2) were sacrificed on the 20th day of gestation, and fetuses were extracted, examined by naked eye and some of them underwent an Alizarin red stain for skeletal examination. Placenta was fixed in 10% formaline solution for histopathological examination. As regard the histological changes in ovary, nicotine caused retardation in the follicular growth, a decrease in healthy follicles and increase in the atretic and cystic follicles. Apoptotic granulosa cells were clearly observed. Fatty degenerative changes in corpora lutea could be observed. In rehabilitation group, there was an improvement in the follicular growth as well as the degenerative changes in corpora lutea but did not reach the control level .In uterus, nicotine caused reduction in the endometrial and myometrial thickness and marked reduction in the endometrial glands. In rehabilitation group, endometrium and myome-

trium looked more or less similar to control apart from reduced endometrial glands in some animals. Placental degenerative changes were observed and reflected on the newborns in the form of abnormal reduction in body size and weight, wrinkled skin, misshaped head, severe kyphosis of body, reduced neck region, micromelia (short limbs), spina bifida and meningoencephalocele. Also skeletal examination of Alizarin red stained fetuses revealed retarded ossification of axial and appendicular skeleton. nicotine adversely influences follicular growth by an increase in apoptotic cell death as well as necrosis. Nicotine induced cell apoptosis and necrosis may represent the mechanisms underlying the well established link between smoking and fertility disorders. Also placental degenerative changes may be considered at least in part, the underlying etiology of the observed fetal anomalies.

Key words : *Nicotine, Uterus, Ovary. Placenta, Pregnancy outcome.*

INTRODUCTlON

Cigarette smoke is a complex mixture of toxic chemicals including nicotine, carbon monoxide, and several recognized carcinogens and mutagens (Stedman, 1968). These toxicants are absorbed through the pulmonary vasculature and transported via the bloodstream causing cytotoxicity, genotoxicity, and tumorigenicity throughout the body (Stillman,.et al.,, 1986.and. Clair,et al.,1994). Nicotine is metabolized primarily by the liver, and to a lesser extent, the lung and kidney ,with the primary metabolite being cotinine (Kyerematen et al., 1990 a&b). In addition to the deleterious effects on cardiovascular and pulmonary physiology, cigarette smoking affects the reproductive system and imposes a number of unique risks specific to women, as smoking have been found to be associated with infertility , ectopic pregnancy (Saraiya et al., 1998), spontaneous abortion (Kendrick et al., 1996) menstrual abnormalities and early onset of menopause (Midgette and Baron, 1990). Interestingly, women who smoke have a decreased risk of breast cancer (Vessey et al., 1983) and endometrial cancer (Cramer et al., 1986). Because these phenomena are all estrogen dependent, it has been suggested that smoking has anti-estrogenic effects (Baron et al., 1990). In fact, female smokers had significantly lower levels of estriol, estradiol, and estrone during the luteal phase of menstrual cycles and tended to have lower levels of these estrogens during the follicular phase compared to nonsmokers (MacMahon et al., 1982). Treatment of rats with nicotine was associated with a decrease in estrogen-dependent parameters including uterine weight, diameter and thickness of the myometrium and endometrium (Patil, et al., 1999). Also, nicotine and M-nicotine (a nicotine metabolite) can induce a sort of luteal insufficiency by inhibiting progesterone release, probably through modula-

tion of the prostaglandin (PG) system (Miceli et al., 2005).

Clearly, additional investigations are needed to clarify the effects of nicotine on follicular steroidogenesis and to demonstrate the nicotine induced histopathological changes in the ovary and uterus.

New ham et al., (1990) ,Went et al., (1990), Ashfaq et al., (2003), Vaglenova et al., (2004), Ronco et al., (2006) and Jauniaux and Burton, (2007) reported that active and passive maternal smoking has been found to cause a damaging effect in every trimester of human pregnancy. Cigarette smoke contains scores of toxins which exert a direct effect on the placental and fetal cell proliferation and differentiation and can explain the increased risk of miscarriage, fetal growth restriction, stillbirth, preterm birth, placental abruption, increased perinatal morbidity, and childhood cognitive and behavioral deficits .All these changes were associated with extensive loss of trophoblasts by apoptosis.

Although many adverse effects of cigarette smoking on reproduction have become clear, the findings of previous studies have largely been contradictory.

Aim of the work: is divided into two main parts: The first focuses on the effects of nicotine on ovarian, uterine and placental structure. The second focuses on the fetal complications associated with maternal smoking during pregnancy. So the present study was carried out to declare the possible mechanisms by which nicotine administration can interfere with female fertility and affect pregnancy outcome, and whether its withdrawal has an improving effect or not.

MATERIAL AND METHODS

A total number of 40 adult female albino Wistar rats aged 3 months old were used in this study. The rats were obtained from animal house, Assiut University. They were housed in stainless steel cages under 12 h light /dark cycle at 25°C and allowed water and food (laboratory chow) add libitum. The experiments reported here were approved by Faculty of Medicine Assiut University ethics committee. The animals were divided into two main groups: (A &B), group A consists of 24 (non pregnant rats) and group B consists of 16 (pregnant rats).

Group A (non pregnant rats) were subdivided into three subgroups, 8 rats each:

1- Control, which were injected with 1 ml 0.9% saline subcutaneously daily for 3 weeks.

2- Nicotine treated group, that were injected daily with nicotine in a dose of 0.4mg/100 gm body weight subcutaneously for 3 weeks which is equivalent to the amount of nicotine passing to the blood of the heavy smoker (Aydos et al., 2001). Nicotine (liquid) was purchased from Fluka Bio Chemica (Switzerland).

3- Rehabilitation group that was injected with nicotine in a dose of 0.4mg/ 100 gm body weight subcutaneously daily for 3 weeks (Aydos et al., 2001), then left for 2 months after stoppage of injection.

Group B (pregnant rats) were subdivided into two subgroups, 8 rats each:

(1) Control group: Rats were left to get pregnant and injected with 0.9% saline subcutaneously daily from the day 6-20 of pregnancy.

(2) Nicotine treated group rats were injected with nicotine in the same dose used in group (A) from the day 6-20 of pregnancy.

Non pregnant animals of group A (1, 2) were sacrificed at the end of 3 weeks, whereas those of groups A (3) were sacrificed 2 months later. Uterine and ovarian(in the diestrus phase) specimens were fixed in 10% formaline solution for histopathological examination using H & E stain.

Pregnant rats of group B (1, 2) were sacrificed on the 20th day of gestation, after being anaesthetized by ether early in the morning to prevent the mothers from devouring any damaging offspring. Before opening either uterine horn the number of living and dead fetuses, as indicated by their movement following a gentle pressure, was recorded (Wilson, 1964). The weight, length and general morphology of fetuses were examined. The placentae were kept in 10% formaline solution for histopathological examination using Hx & E stain for general histological examination, Masson's trichrome for collagen fibres and periodic acid schief for polysacharide (Drury and Wallington, 1980). Two thirds of the fetuses were fixed in Bouin's solution for external and visceral examination. Transverse sections were made in offsprings of control and nicotine treated mothers to investigate the presence of any fetal abnormalities that could be apparent by naked eye.

The other third of fetuses was eviscerated and preserved in 95% alcohol for skeletal examination using Alizarin red stain (Wilson, 1964).

Statistical analysis was done for fetal weight and crown crumb length for both control and nicotine treated groups using statistical package for social sciences version II (SSPS).

RESULTS

3.1. Histological results:

Group (A):

Examination of the ovary of the control animals reveals that the cortex is occupied by follicles in various stages of development and multiple corpora lutea (Fig. 1). Examination of the ovary of the nicotine treated animals reveals multiple cystic and degenerated follicles in various stages of degeneration. Collapsed follicles are observed on the surface of the ovary (Figs. 2 & 3). Multiple apoptotic cells are present among the follicular cells, also degenerated ova are observed in some growing follicles (Figs. 4 & 5). Multiple degenerated granulosa cells with vacuolated cytoplasm and dense nuclei are present (Figs. 6 & 7).

Irregularity in the capsule of some corpora lutea is associated with a large group of pale vacuolated cells immediately beneath the capsule, some of these cells appear anucleated (Figs. 8 & 9).

As regards the rehabilitated animals, there are somewhat increase in the healthy follicles and corpora lutea and reduction in the degenerated follicles and corpora lutea but do not reach the control level (Fig. 10). Mild degenerative changes are observed in ovum, corona radiata and granulosa cells of some animals (Fig. 11). In some corpora lutea, granulosa and theca lutein cells appear with dense nuclei and slightly dark cytoplasm, while others appear with pale vacuolated cytoplasm (Fig. 12).

Examination of the uterus of the control animals reveals the normal histological structure of the endometrium (glands and surrounding stroma), myometrium and perimetrium (Fig. 13). Examination of the uterus of the nicotine treated animals shows a marked reduction in the thickness of both endometrium and myometrium with an observable reduction in the endometrial glands (Fig. 14). In the rehabilitated animals, endometrium and myometrium appear more or less similar to those of control, however fewer glands are observed, compared to the control, in some parts of the endometrium (Fig. 15).

Group (B):

Examination of the placenta of the control animals (in the basal plate) reveals the maternal part decidual cells and multiple maternal blood spaces that are separated by fetal trophoblast cells (fig.16). Multiple branching chorionic villi have blood vessels inside their cores with intact endothelial linning (Figs. 17). Examination of the control placenta by Masson's trichrome demonstrates collagen fibres in moderate amount in the core of villi and in the subtrophoblastic membranes (Fig. 18). Positive periodic acid schief reactions are observed in the basement membranes of the

trophoblasts and those of blood capillaries (Fig. 19).

Examination of the placenta of the treated animals reveals separation of the decidual cells from the basal plate and also from trophoblastic cell columns. Necrotic as well as apoptotic changes are observed in the decidual cells and multiple degenerated cell columns are present (Fig. 20). Wide maternal blood spaces that are surrounded by degenerated decidual cells are also observed (Fig. 21). Apoptotic signs are seen in the decidual cells in the form of fragmentation of the nucleus with separation of the nuclear fragments (Fig. 22). Margination of the nuclear chromatin is associated with cytoplasmic blebbing (Fig. 23), and the nucleus is fragmented into multiple dense rounded globules (Fig. 24). There are multiple cytotrophoblast columns that are formed of degenerated cells (Figs. 25). Multiple degenerated chorionic villi with a relatively small sized blood vessel in their cores as well as degenerated cell columns with an amorphous matrix are observed (Figs. 26 & 27). Discontinuation in the syncytiotrophoblast that leads to free connection between the maternal and fetal blood is present in some animals (Fig. 28). Masson's trichrome demonstrates an increase in the collagen fibres in the core of the villi and in the trophoblastic basement membrane (Fig. 29). Highly positive periodic acid schief reaction is seen in the basement membranes of both the trophoblasts and blood capillaries, so they appeare thicker than those of control placenta (Fig. 30).

3.2. Fertility and pregnancy outcome results:

This study reveals decrease in female rat fertility, however statistically it do not reach the level of significance. The pregnancy outcome of nicotine treated mothers declares a marked reduction in comparison to control mothers, the difference is found to be highly significant (Table 1).

3.3. Gross morphological results of the offsprings :

- As regard fetal body weight, it is found that fetuses of nicotine treated mothers are lighter than those of control mothers. Statistically, the difference in fetal body weight between these two groups of offsprings is recorded to be highly significant (Table 2).

- As regard fetal crown rumb length, it is found that fetuses of nicotine treated mothers are shorter than those of control mothers. Statistically, this difference is reported to be highly significant (Table 2).

3.4. Naked eye examination of offsprings:

The newborn offsprings of nicotine

100 gm body weight daily, a dose which is equivalent to the amount of nicotine passing to the blood of the heavy smoker. This

since they found that benzopyrene, cadmium, or cotinine may have a role in the reduction of blood circulation after exposure to smoke, which can lead to a decreased quantity of mature oocytes. They added that, nicotine may be responsible for the impairment in the vascular endothelial growth factor A which is considered to be one of the substances able to increase ovarian blood circulation, and therefore improves oocyte maturation. Several authors reported necrosis as a form of death in different tissues after nicotine exposure. In human coronary artery endothelial cells, Hakki et al., (2002) found that nicotine significantly inhibits apoptosis by decreased expression level of active caspases. Also, Suzuki et al., (2003) reported an inhibitory effect of smoking in the cardiac apoptosis. Similar observations were reported in the chick ciliary ganglion neurons and in the spinal cord neurons, the later neuron-protective effects were exerted by the increased expression of nerve growth factor (Pugh and Margiotta, 2000 and Garrido et al., 2003). However Pugh and Margiotta (2000) and Garrido et al. (2003) noticed apoptosis, and \ or necrosis in pancreatic cancer cells and in pulmonary tissue after nicotine exposure. Lastely, Bordel, et al. (2006) reported a dose dependent inhibition in the follicular growth and an increased apoptotic cell death specially with a high dose of nicotine in Syrian golden hamsters.

One reason for these conflicting results may be the variation in the nicotine concentration in the different used preparations. Another important factor to consider when comparing the results of past and present studies is the level of ATP inside the tissue which is an important determinant of the form of cell death, since the reduction of ATP inside the tissue is in favor of necrosis. These suggestions were in agreement with the work of Sugano and Ito (2000) who found that nicotine changes the form of H2O2-induced cell death from apoptosis to necrosis in U937 cells by reducing the level of intracellular ATP.

The observed pale vacuolated cytoplasm either in the follicular cells or in the luteal cells of the corpus luteum may indicate a large amount of accumulated lipids that dissolved during the preparation of slides for haematoxyline and Eosin staining that may reflect an impairment in the steroidogenesis. These findings are in accordance with those of the work of several authors who found an increase in the ovarian cholesterol level in nicotine treated rats that indicates the inhibition of the steroidogenesis (Patil et al., 1999). Others reported that the antiestrogenic effects of nicotine may be exerted indirectly by acting at the level of the theca interna to decrease androgen biosynthesis (Sanders et al., 2002) or at the level of granulosa cell aromatase that is responsible for the conversion of androstenedione to estradiol

(Barbieri et al., 1986). However, others suggested that nicotine free base augments estradiol secretion and inhibits progesterone secretion by human granulosa cells in a dose-dependent manner (Bódis et al., 1997). This increase in the estradiol secretion may have a suppressive effect on the progesterone produced by the follicular cells. These suggestions were supported by the work of Fortune and Hanse, (1979) who noticed that high intrafollicular concentrations of estradiol may inhibit follicular progesterone production in vivo before the LH surge .So, nicotine and M-nicotine (a metabolite of nicotine) can induce a sort of luteal insufficiency by inhibiting progesterone release, probably through modulation of the Prostaglandin system (Miceli et al., 2005).

The reduced thickness of the endometrium and myometrium and decrease of number of the endometrial glands observed in the present study may result from the impaired hormonal support (estrogen and progesterone), since estrogen is responsible for the proliferation of the uterine muscles and progesterone is responsible mainly for the development of the uterine glands and glycogen deposition, however the direct toxicity of nicotine or its related metabolites cannot be excluded. The later factor may explain the degenerative and atrophic changes observed specially in the uterine epithelium and glands. These suggestions are in accordance with those of the work of Bao et al. (2002) who investigated the effects of cigarette smoke related hydrocarbons (benzo (a) pyrene) on uterine CYP1A1/2 and 1B1 (enzymes involved in estrogen metabolism), and they suggested that CYP1A2 and CYP1B1 are not induced by(benzo (a) pyrene) in the endometrial cells. Also, it has been found that smoking is associated with decreased incidence of uterine fibroids, endometriosis and uterine cancer, which may reflect inhibitory effects of smoke constituents on uterine cell proliferation and extracellular matrix interactions. In addition, increased miscarriage rate observed among mothers who smoke might be related to direct adverse effects of nicotine, cadmium and polyaromatic hydrocarbons on trophoblast invasion and proliferation (Shiverick and Salafia, 1999).

The observed increased amount of collagen in chorionic villi and increased thickness of subtrophoblastic as well as fetal capillary basement membranes in the present work reflect the degenerative changes that may result from nicotine itself and / or its metabolites and lead to a noticeable retardation in the fetal growth and low birth weight. Nicotine and carbon monoxide both induce degenerative changes that affect the functional component of an organ by reducing its nutritive and excretory functions which may be the cause of low birth

weight babies in smokers (Ashfaq et al., 2003).

The observed degenerative and necrotic changes in the trophoblast cells in the present study may be responsible for the premature aging changes in the placenta that may affect the intrauterine fetal growth. These suggestions are in agreement with those of Ashfaq et al. (2003) who found that the extensive loss of trophoblasts by apoptosis and syncytial buds may lead to hormonal imbalance, premature labour and abnormal outcome of pregnancy in smokers.

The observed increase in cell columns may be explained as a compensatory hyperplasia in the trophoblast cells in a trial to replace the lost trophoblasts, however, the predominant degenerated cells in these columns in the placentae of smoking mothers, may result from the toxaemic effect of nicotine that interferes with the connection of the chorionic villi with the uterine wall that may lead to impairment of the placental barrier and so, the transports between the mother and the fetus. Zdravkovic et al., (2006) supported these suggestions and mentioned that nicotine impaires the development of cell columns by acting through the l-selectin adhesion system.

The observed irregular thickening of the basement membrane of both the trophoblasts and the blood capillaries as well as degeneration of the villous capillary endothelial cells, and reduced diameter of the fetal capillaries in the present work may have a role in the impairment of the feto-maternal exchange of gases and nutrients and so, fetal hypoxaemia .These suggestions are in accordance with those of Larsen et al. (2002) who found that significant increase of the trophoblast volume in the mothers who smoked cigarettes was associated with a significant reduction in the lengths of villous capillaries .Also,the volume density of the fetal vessels in the terminal villi of the smoker's placenta was shown to be decreased and so, the exchange area of the smoker's placenta (Van Der Velde et al., 1983 and 1985). Similarly, Bush et al., (2000) reported that, the increased haematocrits suggests that fetuses of smoking mothers suffer hypoxic stress. However, others reported that some of the fetal changes cannot be explained on this basis and that these may possibly be due either to cadmium toxicity or to accumulation of polycyclic aromatic hydrocarbons in the placenta and/or in the fetal tissues (Van Der Veen and fox, 1982). Zenzes et al. (1997) supported the later opinion and added the immunodetection of cotinine, a major metabolite of nicotine, and benzo (a) pyrene, a potent mutagen and carcinogen, in the embryos as well as granulosa-lutein cells of women in IVF exposed actively or passively to cigarette smoke. In agreement with these results Jauniaux and Burton,

(2007) reported that, in the placenta, smoking is associated from early in pregnancy, with a thickening of the trophoblastic basement membrane, an increase in collagen content of the villous mesenchyme and a decrease in vascularisation.These anatomical changes are associated with changes in placental enzymatic and synthetic functions. In particular,nicotine depresses active amino acid uptake by human placental villi and trophoblast invasion and cadmium decreases the expression and activity of 11 beta- dehydrogenase type 2 which is causally linked to FGR. Maternal smoking also dysregulates trophoblast expression of molecules that govern cellular responses to oxygen tension. The later findings raised the possibility that, the perinatal morbidity associated with cigarette smoking during pregnancy is probably more related to the ischemic and/or toxic effects of several compounds in tobacco smoke, partly on placental function and also directly on the fetus.

The observed perforation in the syncytium in the present study and so connection between fetal and maternal blood as a result of syncytial degenerative and atrophic changes may expose the fetus to toxic substances in the maternal blood. However, Demir et al. (1994) mentioned that focal syncytial necrosis, is associated with degenerated cytoplasmic organelles, abnormalities of the microvilli, decreased syncytial pinocytotic activity that may lead to impairment of placental barrier, and these morphological changes are likely to compromise, rather than assist, transplacental oxygen transfer.

As regard the effect of nicotine withdrawal on the ovarian and uterine tissue, the results of the present work declared that stoppage of nicotine intake leads to improvement of some degenerative changes as the tissue became more or less similar to that of the control. This comes in accordance with the observation of Galal et al. (2005) in the testicular tissue after exposure to nicotineThey suggested that any reduction in the sperm count is potentially reversible. However, Riesenfeld and Oliva, (1988) disagreed with the current findings and reported that the toxic effects of nicotine are irreversible and persisting for the entire life as does infertility. Anyway, it is believed that complete recovery may occur if the period of rehabilitation becomes more prolonged or is accompanied with administration of an adjuvant antioxidant therapy(ElAdlali, 2000).

As regard the effect of nicotine on female fertility and pregnancy outcome, this work revealed a serious influence of nicotine on women's reproductive ability. This may be due to the adverse effect of nicotine on several of the crucial steps within the reproductive process required for achieving a pregnancy or its maintenance,

as this study declared the deleterious effect of nicotine on the female reproductive organs exemplified in the ovary and uterus. Also, its detrimental effect on the placenta cannot be ignored. This result agrees with those of New ham., et al. (1990), Went et al. (1990), Economides and Braithwaite (1994), Cnattingius and Nordstrom., 1996, Nelson et al. (1999), and Gruslin et al. (2001) who stated that maternal smoking is associated with spontaneous abortion, reduced fetal growth, prematurity, and increased perinatal mortality and morbidity. Also, these results agree with the latter observation of Zdravkovic et al. (2005) who suggested that tobacco constituents exert direct effects on cytotrophoblast proliferation and differentiation and help to explain the mechanisms by which smoking negatively affects human pregnancy outcome.

Similar observations were reported by Rostand et al. (1999) in human, they found that the maternal smoking was detrimental to the very early embryo, and even if smoking was stopped, the effects would persist at least for some days and there was no immediate catch-up growth. Also, Pauly et al. (2004) suggested persistent general dependant changes in the behavior of newborn after oral nicotine administration to pregnant mice .However ,these points are in need for further study.

Moreover, Kharrazi et al. (2004) concluded that environmental tobacco smoke exposure in pregnant women adversely affects pregnancy by increasing fetal mortality and preterm delivery at higher exposure levels and showing fetal growth retardation across all levels of exposure. In addition, the results of the study of Sheung et al. (2006) demonstrated that inhalation exposure of pregnant mice to a low dose of mainstream cigarette smoke (MCS) shortened gestation and altered hormone secretory patterns, which are important for maintaining pregnancy.

Considering the fetal growth, the present study declared a significant reduction of the fetal growth parameters in the offsprings of nicotine treated mothers. This could be attributed to the interference of nicotine with the fetal nutrition through its serious effect on the placenta. This comes in accordance with the suggestion of Kulal et al. (2001) who found that children of mothers who were moderate to heavy smokers during pregnancy, had lower birth weight, shorter body length and smaller head circumference than those of non-smokers. They stated that nicotine can adversely affect uterine and placental blood flow by causing constriction of the blood vessels.

Also, Van derVeen and Fox,(1982); Shivericka and Salafia, (1999) stated that retardation of fetal growth could be attributed to ultrastructural changes of the pla-

centa that are believed to contribute to reduced placental nutrient and oxygen transfer. These placental changes are consistent with the association between maternal smoking and fetal growth restriction. Ronco et al. (2006) showed that metallothionein -2 isoform was specifically induced in smokers' placentas. This could be involved in placental cadmium and zinc retention that could contribute to reduce that transference of zinc to the fetus, which in turn, may be associated with detrimental effects on fetal growth, finally leading to the reduced birth weights observed in neonates born from smoking mothers.

These results come in accordance with those of Jauniaux and Burton (2007) who stated that in the fetus, smoking is associated with a reduction of weight, fat mass and most anthropometric parameters and as in the placenta with alterations in protein metabolism and enzyme activity. These alterations are the results of a direct toxic effect on the fetal cells or an indirect effect through damage to, and/or functional disturbances of the placenta.

In addition, Kalinka et al. (2005) found that tobacco smoke exposure is a significant factor inducing increased resistance of umbilical blood flow as measured in 20-24 weeks' gestation. They stated that this could be one of the main mechanisms leading to decrease birth weight and fetal biparietal diameter observed among infants with prenatal exposure to tobacco smoke.

This work revealed a variety of congenital malformations including wrinkled skin, malformed head (scaphocephaly), severe kyphosis, shortened neck region, micromelia, spina bifida and meningoencephalocele. This reflects the severe detrimental effect of nicotine on the developing emberyo. These results agree with those of Saad et al. (1995) who concluded that nicotine had a serious effect on general growth and development as well as on palatogenesis of mice Also, Rostand et al. (1990) found a large number of craniofacial characteristics in the infants of heavy smokers. A great link between cigarette smoke and teratogenicity in rats were found by Reckzeh et al. (1975) and Nelson. et al. (1999). They found also a dose-dependent reduction in fetal body weight, sizes, lengths and bitemporal diameters. Gartner et al. (1997) suggested that nicotine interferes with both palatal and mesenchymal components in utero affecting greatly the tongue development. Furthermore, the studies of Vaglenova et al. (2004) demonstrated that prenatal nicotine exposure produced significant long-term developmental and behavioral teratogenic effects.

In particular, smoking interferes strongly with the fetal brain and pan-

creas biological parameters and induces chromosomal instability, which is associated with an increase in the risk of cancer, especially childhood malignancies (Jauniaux and Burton , 2007).

As regard the mechanisms of nicotine toxicity, increasing evidence points to role for oxidative stress in toxicity by nicotine entailing major body organs, including the lung cardiovascular system, central nervous system, liver, kidney, testis, ovary, pancreas and esophagus (Kovacic and Cooksey, 2005). On the other hand, the results of the work of Seller and Bnait, (1995) indicated that tobacco smoke was not a potent teratogen in the mouse, but that it might have minor effects in those individuals genetically predisposed to an abnormality. Also, the results of the work of Daeninck et al. (1991) revealed that following exposure to nicotine during early gestation, dysmorphogenesis was not observed.

Regarding the effect of nicotine on the central nervous system, the present work revealed the major deleterious effect of nicotine on that system development represented by spina bifida and meningoencephalocele. This supports the suggestion of great relationship between maternal smoking and fetal congenital central nervous system malformations. This comes in accordance with the suggestion of To and Tang, (1999) who concluded that maternal smoking may be associated with particular vascular patterns of damage to the developing brain that can predispose to a hydranencephalic malformation. Moreover, Dempsey and Benowitz, (2001), studies indicated that nicotine adversely affects the developing fetal central nervous system and nicotine effects on the brain may be involved in the pathophysiology of sudden infant death syndrome (SIDS).

Also, Qiao et al. (2005) reported that nicotine elicited oxidative damage to developing neural cells both in vitro and in vivo, a mechanism that explains some of the neurodevelopmental endpoints that are common to that agent.

During a critical developmental period, nicotine exposure produces stimulation of cholinergic receptors in target cells during which provides signals that influence cell replication and differentiation. Accordingly, promotes cholinergic activity that evokes neurodevelopmental damage. Nicotine might induce mitotic arrest in brain cells possessing high concentrations of nicotinic cholinergic receptors (Slotkin et al., 1999).

Furthermore, it was indicated that maternal exposure to nicotine might induce significant neurobehavioral deficits, a decrease in the surviving neurons and an increased expression of glial fibrillary acidic protein in cerebellum and hippocampus of

the offspring on postnatal days 30 and 60 in addition to chromosomal instability in the brain. So , it is suggested that nicotine exposure may produce long-term neuropathological alterations in the offspring (Mattson et al., 2002; Abdel-Rahman et al., 2005, Huizink and Mulder, 2005, Jauniaux and Burton, 2007 and Paz et al., 2007).

Regarding the effect of nicotine on the fetal skeletal system, the present work showed a partial ossification of ribs and an impaired ossification of vertebral column and metatarsal bones. This may be due to toxic effect of nicotine on the development of bone ossification centres. This comes in line with the statement of Seller and Bnait, (1995) who found reduction in the number of skeletal ossification centres, and reported that there was a developmental delay. In C7BL mice, one rib abnormality occurred, in the curly tail mutant mice, there was a modest increase in the frequency of open spina bifida and exencephaly.

The delayed ossification in both axial and appendicular skeletons noticed in this work coincides with the results of the work of Paulson et al. (1994) who concluded that high dose result in significant growth retardation and decreased ossification.

This study results agree with the results of Nelson. et al. (1999) who concluded that maternal passive smoking during pregnancy produces a widespread ossification abnormalities in all exposed groups regardless of the dose. Such a retardation was not limited to a particular bone. That results supported epidemiologic data on developmental toxicity of passive smoking and further provided evidence on an unfavorable osteopathic effect of side stream exposure of mother on fetal development. Furthermore, Carmines et al. (2003)reported that with in utero exposure to cigarette smoke, skeletal examinations revealed delayed ossification (supraoccipital and sternebrea) in fetuses.

On the other hand, and on the contrary to the above mentioned research results, a multivariate analysis as regard smoking and the occurrence of congenital malformations and spontaneous abortions was done by Hemminki et al. (1983). They found that the possibility for the smoker's child to be born with central nervous system defects, oral cleft, or musculoskeletal malformations revealed statistically non significant differences. That controversy in the results of the different researches on nicotine teratogenic effects may be due to the differences in the doses and routes of administration of nicotine. Also, it may be due to variation in the genetic predisposition and sensitivity to nicotine.

Lastly, it is our recommendations for

preventive measures to be undertaken and to encourage females in the reproductive age and pregnant women to stop smoking and avoid passive exposure to tobacco smoke from the beginning of pregnancy.

In the end, it is our hope that the present study results super-light upon the adverse effects that smoking imparts on the reproductive health. Perhaps, this will persuade individuals to stop and stimulate further research into this health problem.

Acknowledgment :

The authors gratefully acknowledge critical help by Dr .Gamal Hasan Abdel-Sabour,Department of Zoology,Faculty of Science Assiut University.

Table (1): Effects of nicotine on pregnancy outcome.

Paired samples test

Group		Mean ± S. D.	t	Sig. (2-tailed)	Correlation (r)
Pair (1)	Number of pregnant control animals - number of pregnant nicotine treated animals	0.3750 ± 0.5175	2.049	0.080	
Pair (2)	Number of fetuses of control animals – number of fetuses of nicotine treated animals	4.2500 ± 3.1053**	3.871	0.006	- 1.000
Pair (3)	Number of living fetuses of control animals of living fetuses of nicotine treated animals	5.3750 ± 2.1998**	6.911	0.000	- 0.980

P<0.05

Table (2): Influence of nicotine on fetal growth .

Group	Fetal weight (gm) (X ± SD)	crown rumb length (cm)
Control (8)	1.24 ± 3.3 E-02	2.28 ± 0.11
Treatment (nicotine) (8)	0.25** ± 5.23 E-02	1.16** ± 0.10

P<0.05

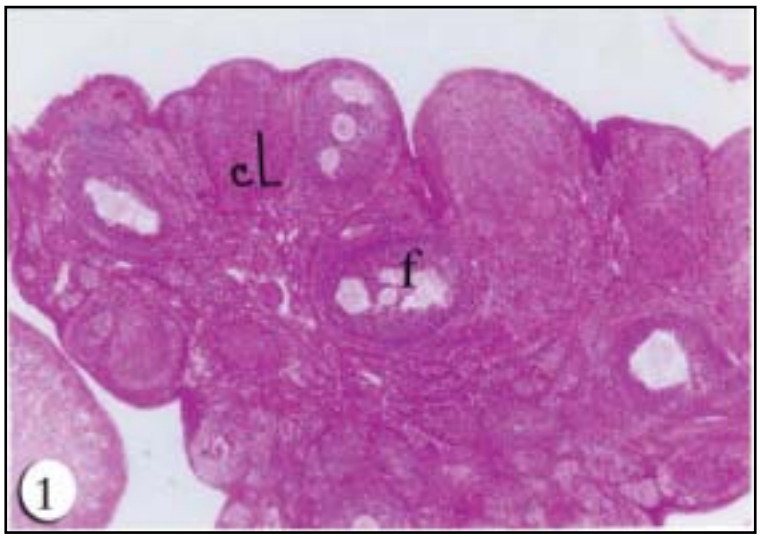

Fig. (1) : A photomicrograph of the ovary of a control animal, (group A/1)showing the cortex occupied by follicles (f) in various stages of development and multiple corpora lutea (CL). *(Hx & E 40)*.

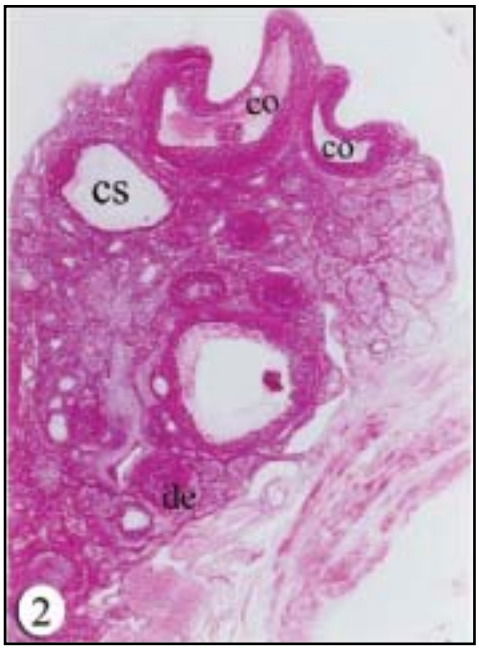

Fig. (2) : A photomicrograph of the ovary of a nicotine treated animal (group A2) showing multiple cystic folliles (cs) and degenerated follicles (de) in various stages of degeneration. Notice two collapsed follicles (co) on the surface of the ovary. *(Hx & E 40)*.

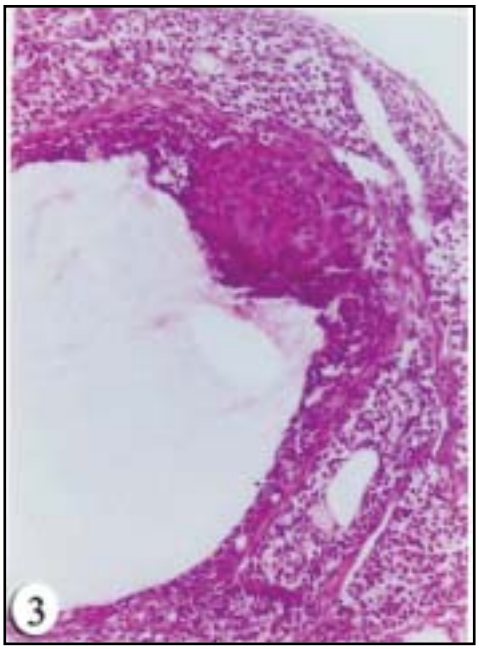

Fig. (3) : A magnified part of group A2 ovary showing a large cystic follicle with localized thickening at one side which is formed of multiple dark degenerated granulosa cells. *(Hx &E 200)*.

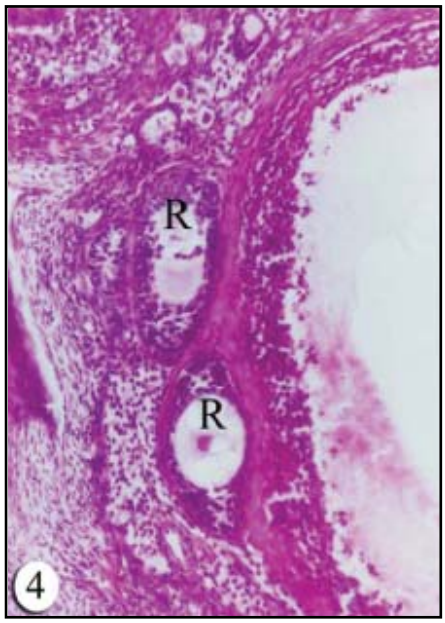

Fig. (4) : A magnified part of group A2 ovary showing a part of cystic follicle with detached apoptotic cells (arrow) towards the lumen. Notice the two adjacent follicles with degenerated ova (R) and surrounded by degenerated follicular cells. *(Hx &E 200).*

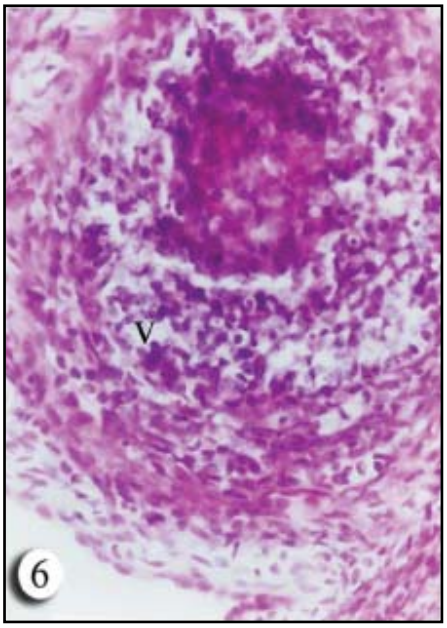

Fig. (6): A magnified part of group A2 ovary showing an atretic growing follicle with no observable ovum. Multiple vacuoles (v) of degenerated granulosa cells are present between the surrounding dark cells. *(Hx &E 400).*

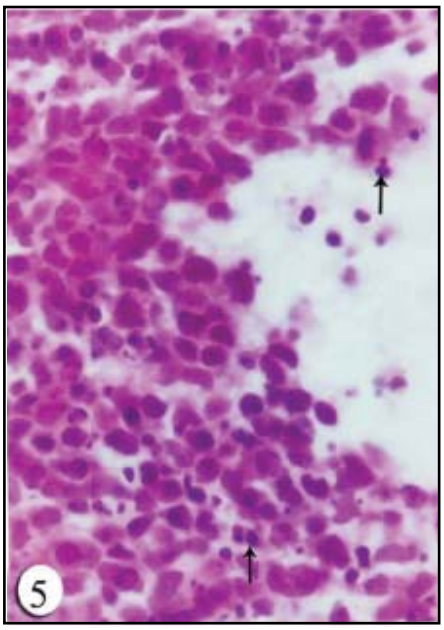

Fig. (5): A magnified part of group A2 ovary showing a part of the follicular wall with multiple apoptotic cells (≠) between the surrounding dark cells. *(Hx & E 1000).*

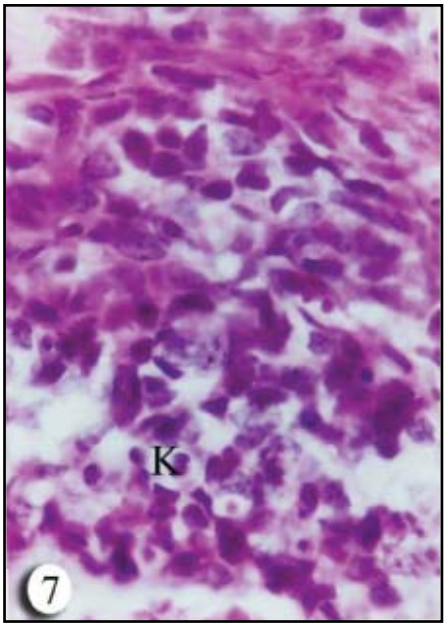

Fig. (7): A magnified part of the previous picture showing condensed nuclei that are surrounded by vacuolated cytoplasm (K). *(Hx & E 1000)*

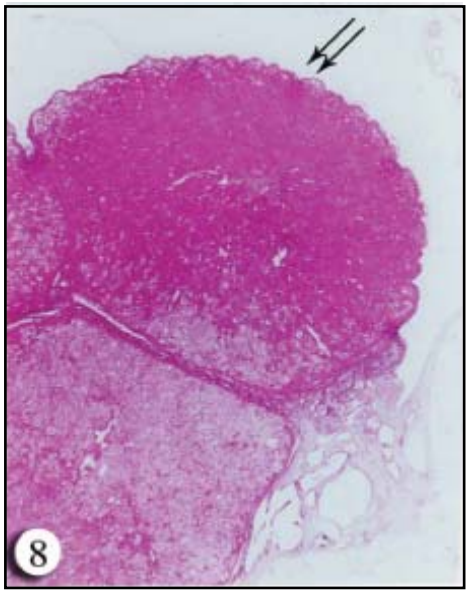

Fig. (8): A photomicrograph of the group A2 ovary showing multiple corpora lutea with marked irregularity in their capsules (two arrows) *(Hx & E 40)*.

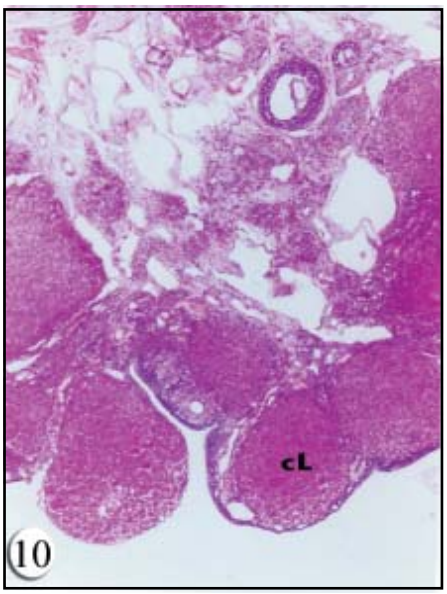

Fig. (10): A photomicrograph of the rehabilitation group ovary (groupA3) showing multiple more or less healthy follicles and corpora lutea (CL) *(Hx & E 40)*.

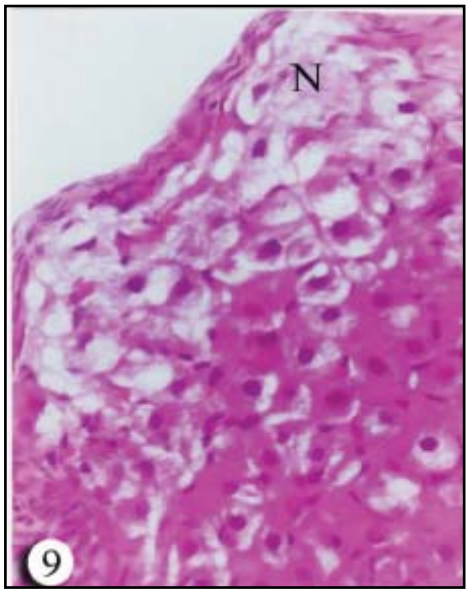

Fig. (9): A magnified part of the group A2 ovary showing a part of corpus luteum with a large group of pale vacuolated cells immediately beneath the capsules, some of these cells appear anucleated (N). *(Hx & E 400)*.

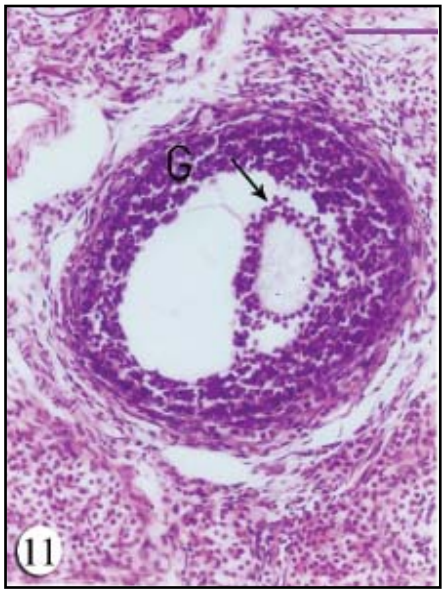

Fig. (11): A magnified part of group A3 ovary showing a well rounded secondary follicle with a degenerated ovum. Corona radiata (arrow) and granulosa cells (G) look dense in comparison to those of control *(Hx & E 200)*.

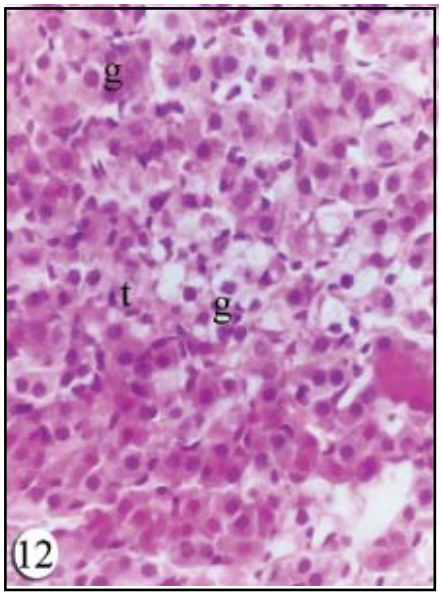

Fig. (12): A magnified part of group A3 ovary showing a part of the corpus luteum with few pale vacuolated cells. Granulosa and theca lutein cells have dense (g & t) nuclei and slightly dark cytoplasm *(Hx & E 400)*.

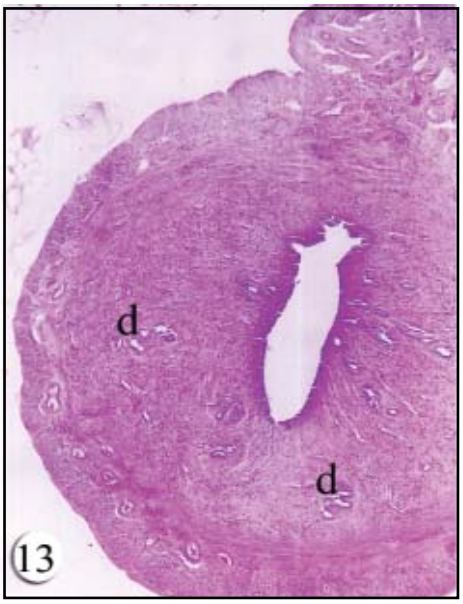

Fig. (13): A photomicrograph of the uterus of group A1 animals showing the endometrium (glands (d) and surrounding stroma), myometrium and perimetrium *(Hx & E 40)*.

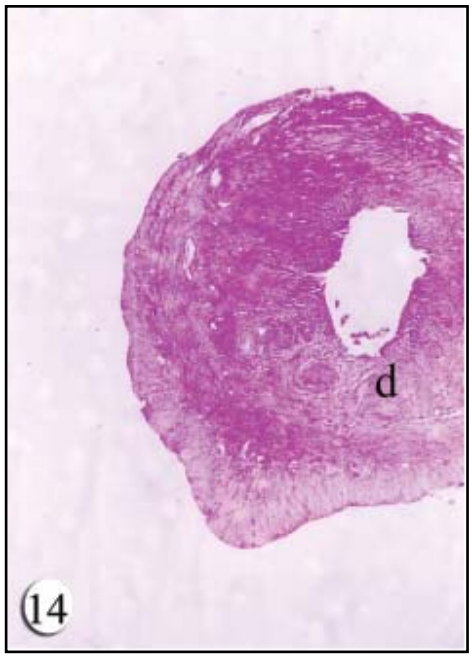

Fig. (14): A photomicrograph of the uterus of group A2 animals showing a marked reduction in the thickness of both endometrium and myometrium with an observable reduction in the endometrial glands (d) *(Hx & E 40)*

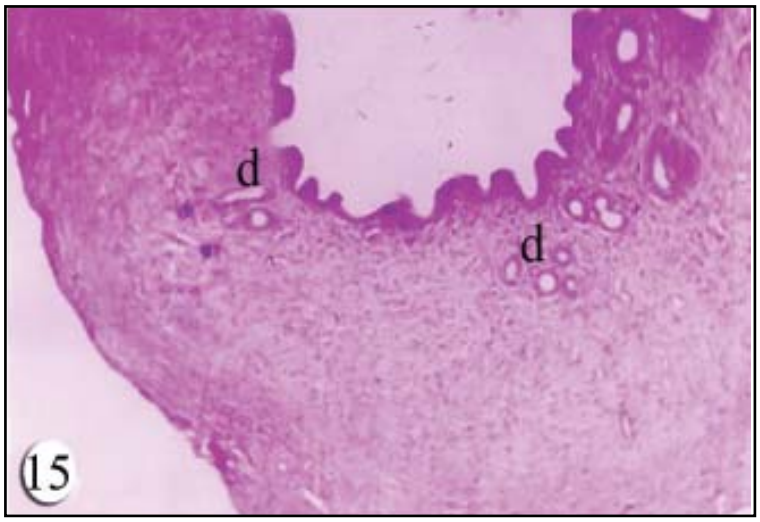

Fig. (15): A photomicrograph of the uterus of group A3 animals showing that the endometrium and myometrium are more or less similar to those of control, however, the glands (d) appear fewer in some parts of the endometrium. *(Hx & E 40).*

Fig. (16): A photomicrograph of the basal plate of the control placenta (groupB1) which constitutes the maternal part showing decidual cells(dc), multiple maternal blood spaces(ms) separated by fetal trophoblast cells. *(Hx & E 40).*

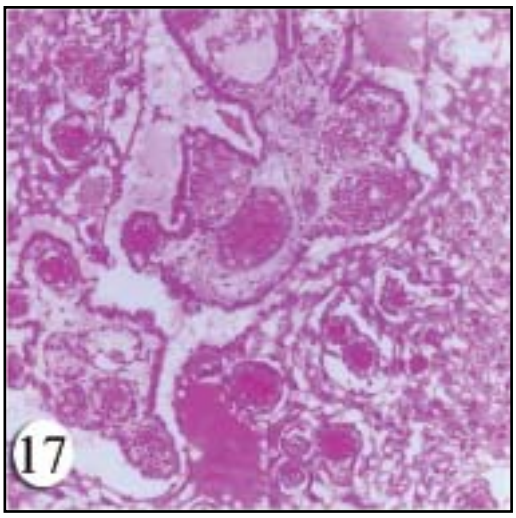

Fig. (17): A photomicrograph of the placenta of the group B1 animals showing multiple floating branching chorionic villi. *(Hx & E 100)*

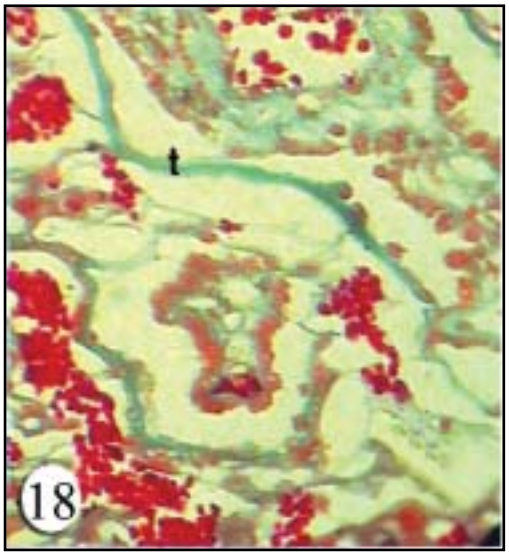

Fig. (18): A photomicrograph of the placenta of the group B1 animals showing the collagen fibres in the core of the villi and in the trophoblastic basement membrane (t). *(Masson 's trichrome X400)*

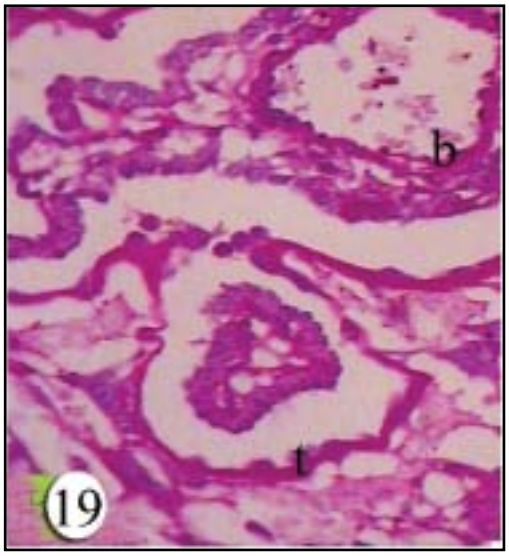

Fig. (19): A photomicrograph of the placenta of the group B1 animals showing a positive reaction in the basement membranes of the trophoblasts(t) and those of the blood capillaries (b). *(PAS X400)*

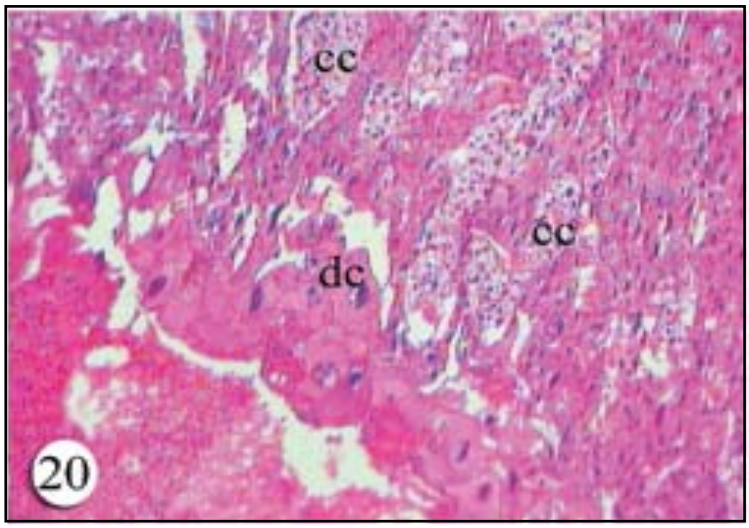

Fig. (20): A photomicrograph of the placenta of the nicotine treated animals (group B2) showing separation of the decidual cells from the basal plate and also from the trophoblastic cell columns. Necrotic as well as apoptotic changes are observed in the decidual cells (dc). Notice multiple degenerated cell columns (cc) *(Hx & E 40)*.

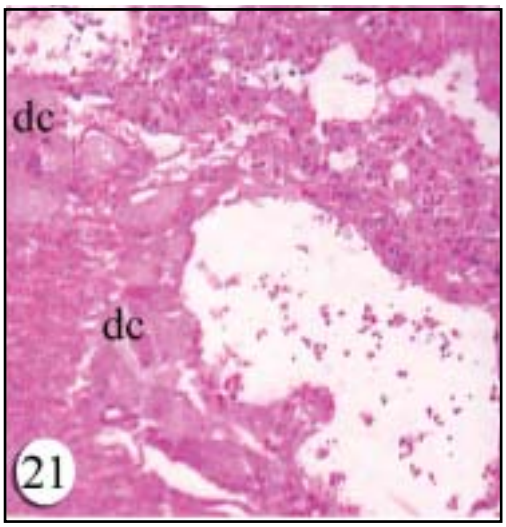

Fig. (21): A photomicrograph of the placenta of group B2 animals showing maternal blood spaces that are surrounded by degenerated decidual cells(dc). *(Hx & E 40).*

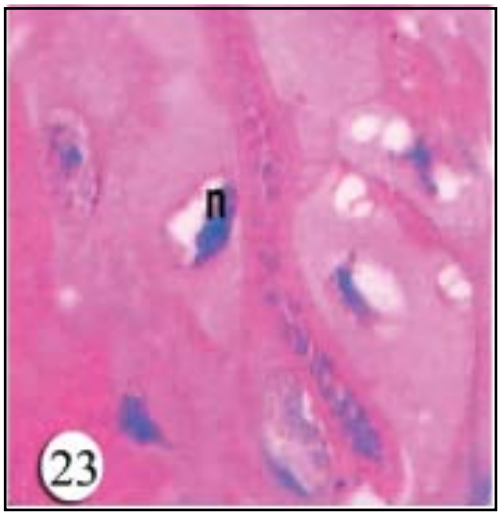

Fig. (23): A magnified view of decidual cells of the group B2 animals showing margination of the nuclear chromatin (n) associated with cytoplasmic blebbing *(Hx & E 1000).*

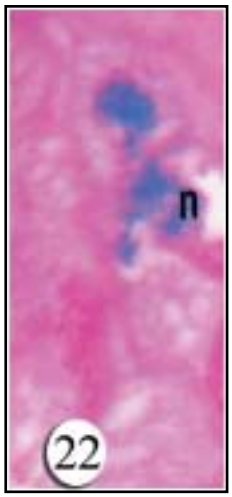

Fig. (22): A magnified view of decidual cells of the group B2 animals showing fragmented nuclei (n). *(Hx & E 1000).*

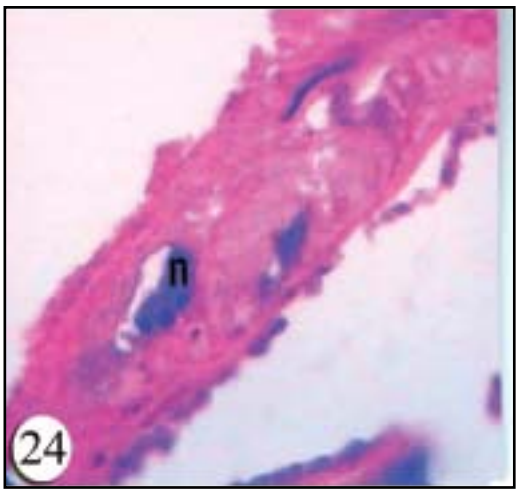

Fig. (24): A magnified view of decidual cells of the group B2 animals showing fragmented nuclei into multiple dense rounded globules (n). *(Hx & E 1000).*

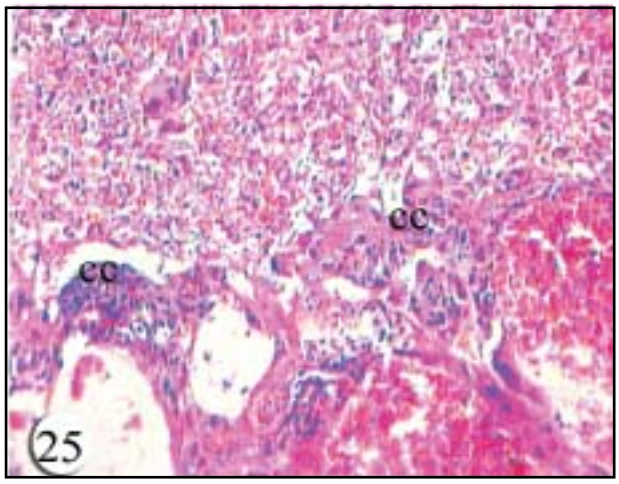

Fig. (25): A photomicrograph of the placenta of the group B2 animals showing multiple cytotrophoblastic columns (cc) that are formed of degenerated cells. *(Hx & E 40).*

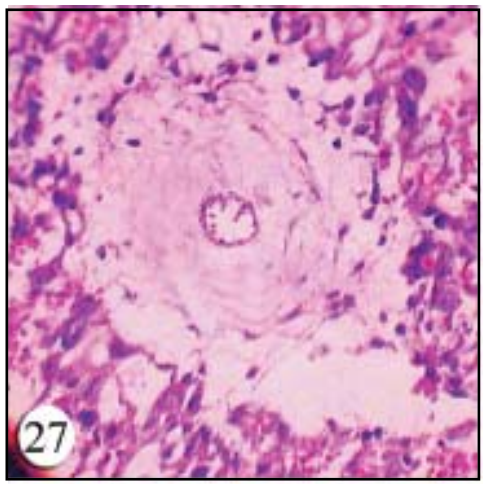

Fig. (27): A magnified part of a degenerated chorionic villus of the group B2 placenta showing a relatively small vessel in the core and no observable cyto. or syncytiotrophoblasts *(Hx & E 400).*

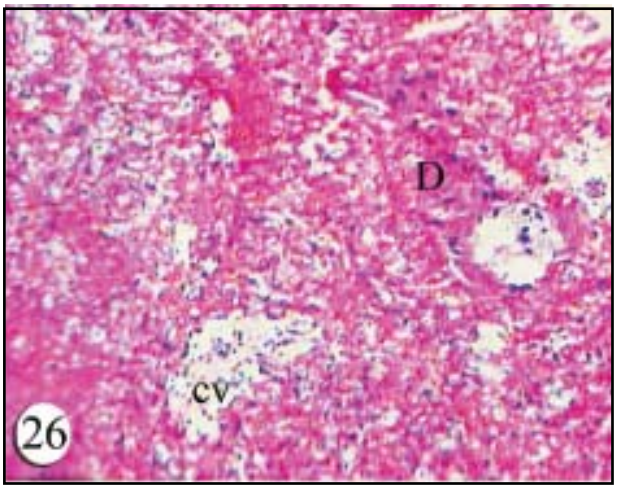

Fig. (26): A photomicrograph of the placenta of the group B2 animals showing multiple degenerated chorionic villi (cv) with a relatively small sized blood vessels in their cores .Notice the degenerated cell columns with an amorphous matrix(D) *(Hx & E 40).*

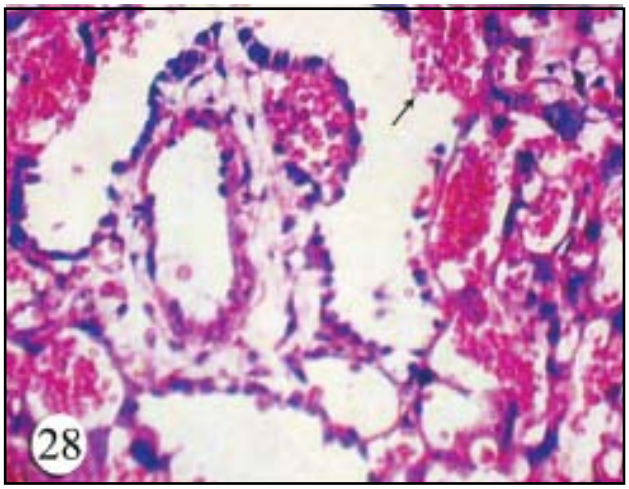

Fig. (28): A magnified chorionic villus of the group B2 animals showing a discontinuation in the syncytiotrophoblast (arrow) that leads to a free connection between the maternal and fetal blood. *(Hx & E 400).*

Fig. (29): A photomicrograph of the placenta of the group B2 animals showing an increase in the collagen fibres in the core of the villi (cv) and in the trophoblastic basement membrane (t). *(Masson 's trichrome X 400)*

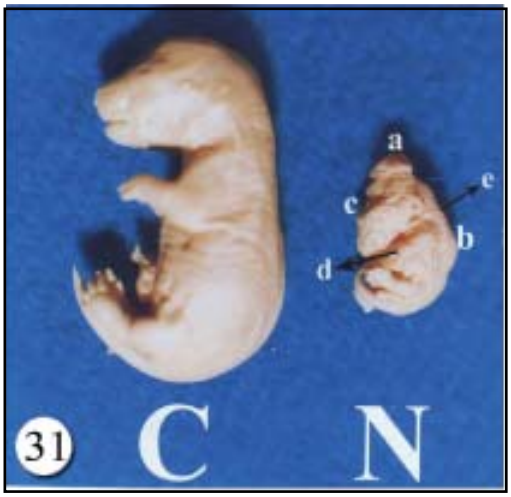

Fig. (31): A lateral view photograph of offsprings of control (C) and nicotine treated (N) mothers. The nicotine treated group offspring shows several congenital anomalies including marked reduction in body size, malformed head, meningoencephalocele (a), spina bifida(b),depressed frontal area of the head(c), micromelia (d) and kyphosis (e).

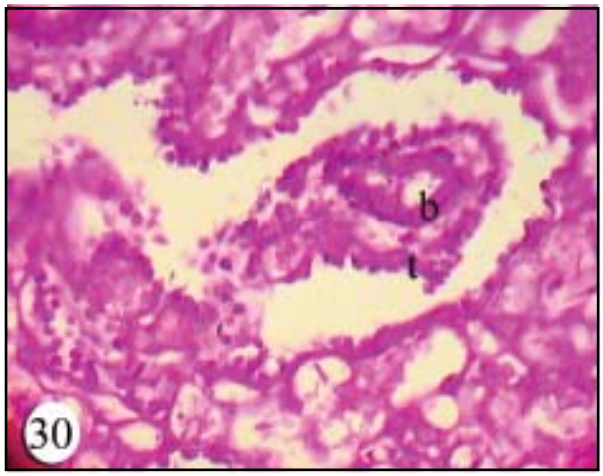

Fig. (30): A photomicrograph of the placenta of the group B2 animals showing a highly positive reaction in the basement membrane of both the trophoblasts (t) and the blood capillaries(b) *(PAS X400)*.

Fig. (32): A lateral view photograph of a nicotine treated group offspring showing an area of subcutaneous heamorrhage *(arrow)*.

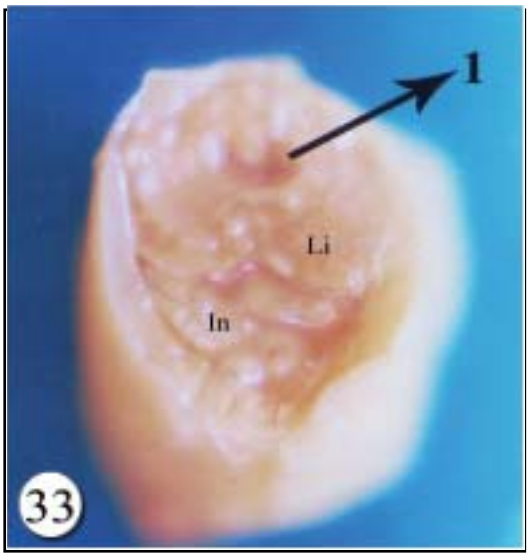

Fig (33): A photograph of a transverse section in the abdominal region of a nicotine treated group offspring showing an abnormal spinal cord; spina bifida with some degrees of rachischisis (failure of fusion of several vertebral arches) and myeloschisis (failure of closure of neural folds) (1). (Note) : Li = liver, and In =intestine.

Fig. (35): A lateral view photograph of a nicotine treated group offspring stained with Alizarin red showing partial ossification of ribs (1).

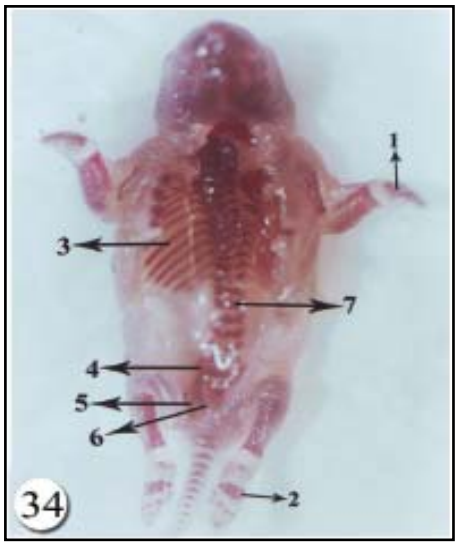

Fig. (34): A ventral view photograph of a control rat group offspring stained with Alizarin red showing complete ossification of the metacarpal (1), metatarsal (2), ribs (3), ilium (4), ischium (5), pubis (6),and vertebral column (7) bone centres.

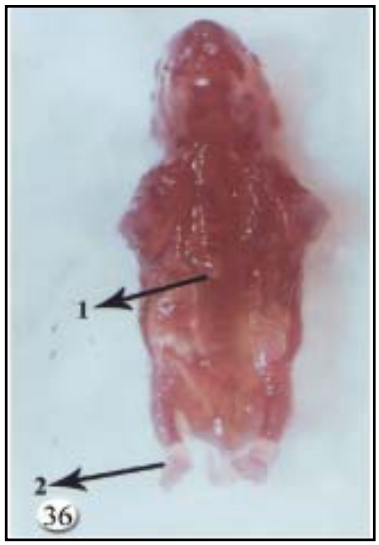

Fig. (36): A lateral view photograph of a nicotine treated group offspring stained with Alizarin red showing an impaired ossification of vertebral column (1), and metatarsal bones (2).

REFERENCES

Abdel-Rahman, A.; Dechkovskaia, A. M.; Sutton, J. M.; Chen, W. C.; Guan, X.; Khan, W. A. and Abou-Donia M. B. (2005) : "Maternal exposure of rats to nicotine via infusion during gestation produces neurobehavioral deficits and elevated expression of glial fibrillary acidic protein in the cerebellum and CA1 subfield in the offspring at puberty", Toxiology, 209 : 245-61.

Ashfaq, M.; Janjua, M. Z. and Nawaz, M.. (2003) : "Effects of maternal smoking on placental morphology". J. Ayub Med Coll Abbottabad, 15 : 12-15.

Aydos, K.; Guven, M. C.; Can, B. and Ergun, A., (2001) : "Nicotine toxicity to the ultrastructure of the rat testis". BJU Int, 88 : 622-626.

Bao, H.; Vepakomma, M. and Sarkar, A M. (2002) : "Benzo (a) pyrene exposure induces CYP1A1 activity and expression in human endometrial cells". J Steroid Biochem Mol Bioly, 81 : 37-45.

Barbieri, R. L.; McShane, P. M. and Ryan, K.J. (1986) : "Constituents of cigarette smoke inhibit human granulosa cell aromatase". Fertil. and Steril., 46 : 232-236.

Baron, J. A.; LaVecchia, C. and Levi, F., (1990) : "The antiestrogenic effect of cigarette smoking in women". Am. J. Obstet. Gynecol., 162 : 502-514.

Bo-dis, J.; Hanf, V.; Torok, A.; Tinneberg, H. R.; Borsay, P. and Szabo, I. (1997) : "Influence of nicotine on progesterone and estradiol production of cultured human granulosa cells. Early pregnancy: biology and medicine" the official Journal of the Society for the Investigation of Early Pregnancy, 3 : 34-37.

Bordel, R.; Laschke, M. W.; Manger, M. D. and Vollmar, B. (2006) : "Nicotine does not affect Vascularisation but inhibits growth of freely transplanted ovarian follicles by inducing granulosa cell apoptosis". Human Reproduction, 21 : 610-617.

Bush, P. G.; Mayhew, T. M.; Abramovich, D. R.; Aggett, P. J.; Burke, M. D. and Page, K. R. (2000) : "A quantitative study on the effects of maternal smoking on placental morphology and cadmium concentration". Placenta, 21 : 247-56.

Carmines, E. L.; Gaworski, C. L.; Fagi, A. S. and Roiendran, N. (2003) : "In utero exposure to 1R4F reference cigarette smoke: evaluation of developmental toxicity". Toxicol. Scis., 75 : 134-147 .

Clair, D. K.; Jordan, J. A.; Wan, X. S. and Gairola, C. G. (1994) : "Protective role of manganese super-oxide dismutase against cigarette smoke-induced

cytotoxicity". J. Toxicol. Environ., Health, 43 : 239-249.

Cnattingius, S. and Nordstrom M. L. (1996) : "Maternal smoking and feta- infant mortality biological pathways and public health significance". Acts paediats, 85 : 1400-1402.

Cramer, D. W.; Wilson, E. and Stillman, R. J. (1986) : "The relation of endometriosis to menstrual characteristics, smoking and exercise". JAMA, 255 : 1904-1908.

Daeninck, P. J.; Messiah, N. and Persaud T. V. (1991) : "Intrauterine development in the rat. following continuous exposure to nicotine from gestational day 6 through 12". Anat Anz ., 172 : 257-261.

Demir, R.; Demir, A. Y. and Yinanc, M. (1994) : "Structural changes in placental barrier of smoking mother. A quantitative and ultrastructural study". Pathol Res Pract., 190 : 656-667.

Demiralay, R.; Gürsanb, N. and Erdemb, H. (2006) : "The effects of erdosteine, N-acetylcysteine, and vitamin E on nicotine-induced apoptosis of pulmonary cells". Toxicology, 219 : 197-207.

Dempsey, D. A. and Benowitz N. L (2001) : "Risks and benefits of nicotine to aid smoking cessation in pregnancy". Drug Saf., 24 : 277-322.

Drury, R. and Wallington, E. A. (1980) : "Carleton's Histological Techniques." 5th ed. Oxford University Press, 235-241.

Economides, D. and Braithwaite J. (1994) : "Smoking, pregnancy and the fetus". TR Soc Health, 114 : 198-201.

ELAdlali, (2000) : "The role of selenium in resolution of reproductive toxicity of methoxyethanol and nicotine of male albino rat". MD. Thesis, Faculty of science, Mansura University.

Fawcett, D. W. (1994) : A Text Book of Histology, 11th ed. W.B. Saunders Co Philadelphia., 769-799.

Fortune, J. E. and Hansel, W. (1979) : "The effects of 17-estradiol on progesterone secretion by bovine theca and granulosa cells". Endocrinology, 104 : 1834-1838.

Galal, A. T.; Sayed, S. A.; El-Meligy, M. M. and Abd-El-Samea, A. R. (2005) : "Stereological and histological studies on the effect of nicotine administration and its withdrawal on the seminiferous tubules of the albino rat testis". Med. J. Cairo. Univ., 73:69-105.

Galitovsky, V.; Chowdhury, P. and. Zharov, P. V. (2004) : "Photothermal de-

tection of nicotine-induced apoptotic effects in pancreatic cancer cells". Life Sciences. 75(22), 15, 2677-2687.

Garrido, R.; King-Pospisil, K.; Son, K. W.; Hennig, B. and Toborek, M. (2003) : "Nicotine upregulates nerve growth factor expression and prevents apoptosis of cultured spinal cord neurons". Neurosci. Res., 47 : 349-355.

Gartner, L P.; Saad, A. Y. and Hiatt, T. L. (1997) : "Effects of nicotine on tongue development in the CD-1 mouse". Eur J. Morphol., 35 : 337 - 43.

Gocze, M. P. and Freeman, D. A. (2000) : "Cytotoxic effects of cigarette smoke alkaloids inhibit the progesterone production and cell growth of cultured MA-10 Leydig tumor cells". Eur. J. Obstet & Gynecol. and Reprod. Biolo., 93 : 77-83.

Gruslin, A.; qiu, Q. andTsang, B. K. (2001) : "Influence of maternal smoking on trophoblast apoptosis throughout development: possible involvement of xiap regulation". Biology of Reproduction, 65 : 1164-1169.

Hakki, A.; Friedman, H. and Pross, S. (2002) : "Nicotine modulation of apoptosis in human coronary artery endothelial cells". Int Immunopharmacol, 2 : 1403-1409.

Helen, K.; Krishnakumar, P. L.; Vijayammal, K. T. and Augusti, A., (2003) : "A comparative study of antioxidants S-allyl cysteine sulfoxide and vitamin E. on the damages induced by nicotine in rats". Pharmacology, 67 : 113-117.

Hellermann, G. R.; Nagy, S B.; Kong, X.; Richard, F.; Lockey, R. F. and Mohapatra, S. S. (2002) : "Mechanism of cigarette smoke condensate-induced acute inflammatory response in human bronchial epithelial cells". Respir. Res., 3 : 22.

Hemminki, K.; Mutatnen, P. and Saloniemi, I. (1983) : "Smoking and the occurrence of congenital malformations and spontaneous abortion: multivariate analyics". Am. J. Obstet. Gynecol., 145 : 61 -66.

Huizink A. C. and Mulder E. J. (2006) : "Maternal smoking, drinking or cannabis use during pregnancy and neurobehavioral and cognitive functioning in human offspring". Neurosci and Biolehavl. Rev., 30 : 24-41.

Jauniaux, E. and Burton, G. J., (2007) : "Morphological and biological effects of maternal exposure to tobacco smoke on the feto-placental unit". Early Human Development, 83 : 699-706.

Jay, M.; Kojima, S. and Gillespie, M. N. (1986) : "Nicotine potentiates superox-

ide anion generation by human neutrophils". Toxicol. App. Pharmacol, 86 : 484-487.

Kalinka, J.; Hanke, W. and Sobala, W., (2005) : "Impact of prenatal tobacco smoke exposure, as measured by midgestation serum cotinine levels, on fetal biometry and umbilical flow velocity waveforms". Am. J. Perinatol., 22 : 41-47.

Kendrick, J. S.; Tierney, E. F. and Lawson, H. W. (1996) : "Previous cesarean delivery and the risk of ectopic pregnancy. Obstet. Gynecol., 87 : 297-301.

Kharrazi, M.; Delorenze, G. N.; Kaufman, F. L.; Eskenazi, B.; Bernert, J. T.; Graham, S.; Pearl, M. and Pirkle, J. (2004) : "Environmental tobacco smoke and pregnancy outcome". Epidemiology, 15 : 660-670.

Kovacic, P. K. and Cooksey A. (2005) : "Iminium metabolite mechanism for nicotine toxicity and addiction : oxidative stress and electron transfer". Med. Hypotheses., 64 : 104-111.

Kulal, L.; Hruba, D. and Tyrlik, M. (2001) : "European Longitudinal Study of the Pregnancy and childhood : smoking and damages- of reproduction : evidence of ELSPAC". Cent. Eur. J. Public Health, 9 : 59-63.

Kyerematen, G. A.; Morgan, M.; Warner, G.; Martin, L. F. and Vessell, E. S. (1990b) : "Metabolism of nicotine by hepatocytes". Biochem. Pharmacol., 40 : 1747-1756.

Kyerematen, G. A.; Morgan, M. L.; Chattopadhyay, B.; DeBethizy, J. D. and Vesell, E. S. (1990a) : "Disposition of nicotine and eight metabolites that are longer lived than cotinine". Clin. Pharmacol. Ther. 48 : 641-651.

Larsen, L. G.; Clausen, H. V. and Jønsson, L., (2002) : "Stereologic examination of placentas from mothers who smoke during pregnancy". Am J. Obstet Gynecol., 186 : 531-537.

MacMahon, B.; Trichopoulos, D.; Cole, P. and Brown, J. (1982) : "Cigarette smoke and urinary estrogens". N. Engl. J. Med., 307 : 1062-1065.

Mattson, S. N.; Calarco, K. E.; Chambers, C. D. and Jones, K. L. (2002) : "Interaction of maternal smoking and other factors in pregnancy exposures: analytic considerations". Neurotoxicol. Teratol., 24 : 359-3 67.

Miceli, F.; Minici, F.; Tropea, A.; Catino, S.; Orlando, M.; Lamanna, G.; Sagnella, F.; Tiberi, F.; Bompiani, A.; Mancuso, S.; Lanzone, A. and Apa, A., (2005) : "Effects of nicotine on human luteal cells in vitro": A possible role on reproductive

outcome for smoking women. Biol. of Reprod., 72 : 628-632.

Midgette, A. S. and Baron, J. A. (1990) : "Cigarette smoking and the risk of natural menopause". Epidemiology, 1 : 474-479.

Motejlek, K.; Palluch, F.; Neulen, J. and Grümmer, R. (2006) : "Smoking impairs angiogenesis during maturation of human oocytes". Fertil and steril. 86 : 186-191.

Nelson, E.; Jodscheit, K. and Guo, Y. (1999) : "Maternal passive smoking during pregnancy and fetal developmental toxicity. Part 1 : gross morphological effects". Hum. Exp. Toxicol., 18 : 252-256.

New ham, J. P.; Patterson, L.; James, I. and Reid, S. E. (1990) : "Effects of maternal cigarette smoking on ultrasonic measurements of fetal growth and on Doppler flow velocity waveforms". Early Hum. Dev., 24:23-36.

Patil, S.; Patil, S.; Bhaktaraj, B. and Patil, S. B. (1999) : "Effect of graded doses of nicotine on ovarian and uterine activities in albino rats". Indian J. Exp. Biol., 37 : 184-186.

Paulson, R. B.; Shanfeld, J.; Mullet, D.; Cole, J. and Paulson, J. O. (1994) : "Prenatal smokeless tobacco effects on the rat fetus". J. Craniofac. Genet. Dev. Biol., 14:16-25.

Pauly, J. R.; Sparks, T. A.; Hauser, K. E. and Pauly, T. H. (2004) : "In utero nicotine exposure causes persistent, gender - dependant changes in locomotor activity and sensitivity to nicotine in C57 B 1/6 mice". Int. J. Dev. Neurosci., 22 : 329 - 337.

Paz, R.; Barsness, B.; Martenson, T.; Tanner, D. and Allan, A. M. (2007) : "Behavioral teratogenicity induced by non-forced maternal nicotine consumption". Neuropsychopharmacol. 32 : 693-699.

Pugh, C. P. and Margiotta, F. J. (2000) : "Nicotinic acetylcholine receptor agonists promote survival and reduce apoptosis of chick ciliary ganglion neurons". Molecular and Cellular Neuroscience, 15 : 113-122.

Qiao, D.; Seidler, F. J. and Slotkin, T. A. (2005) : "Oxidative mechanisms contributing to the developmental neurotoxicity of nicotine". Toxicol. Appl. Pharmacol., 1 : 17-26.

Reckzeh, G.; Dontewill, W. and Leuschner, F. (1975) : "Testing of cigarette smoke inhalation for teratogenicity in rats". Toxicology, 4 : 289 -295.

Riesenfeld, A. and Oliva. H. (1988) : "The effect of nicotine on the fertility, cytology and life span of rats". Acta Anatomica (Basel), 131 : 171-176.

Riyadh Daily Newspaper, (2004) : Wednesday 31; 13067.

Ronco, A. M.; Garrido, F.; Llanons, M. N. (2006) : "Smoking specifically induces metallothionein - 2 isoform in human placenta at term". Toxicology, 223 : 46-53.

Rostand, A.; Kaminski, M.; Lelong, N.; Dehaene, P.; Delestret, I.; Klein - Bertrand, C.; Querleu, D. and Crepin, G. (1990) : "Alcohol use in Pregnancy, Craniofacial features, and fetal growth". J. Epdemiol. Community Health, 44 : 302 - 306.

Saad, A. Y.; Gartner, L. P. and Hiatt, J. L. (1995) : "Teratogenic effects of nicotine on Palate formation in mice". Biol. Struct. Morphol., 91 : 31-35.

Sanders, R. S.; Cuneo, P. S. and Turzillo, M. A. (2002) : "Effects of nicotine and cotinine on bovine theca interna and granulosa cells". Reproductive Toxicology, 16 : 795-800.

Saraiya, M.; Berg, C. and Kendrick, J. S. (1998) : "Cigarette smoking as a risk factor for ectopic pregnancy". Gynecology, 178 : 493-498.

Schardein, J. L. (2000) : Tobacco Smoking In : Chemically Induced Birth Defects 3rd ed., Marcel Dekker, New York, P.P. 716-722.

Seller, M. J. and Bnait, K. S. (1995) : "Effects of tobacco smoke inhalation on the developing mouse embryo and fetus". Reprod. Toxicol., 9 : 449 -459.

Sheung, P. N.; Bernard, G.; Steinetz, Salamia G., Lasano, and Judith, T.; Zelikoff (2006) : "Hormonal changes accompanying cigarette smoke - induced preterm births in a mouse model". Exp. Biol. Med., 231 : 1403-1409.

Shivericka, K. T. and Salafia, C. (1999) : "Cigarette smoking and pregnancy I : ovarian, uterine and placental effects". Placenta, 20 : 265-272.

Slotkin, T. A.; Epps, T. A.; Steger, M. L.; Sawyer, K. J. and Seidler, F. J. (1999) : "Cholinergic receptors in heart and brainstem of rats exposed to nicotine during development: implications for hypoxia tolerance and perinatal mortality". Brain Res Dev., 12 : 1-12.

Stedman, R. L. (1968) : "The chemical composition of tobacco and tobacco smoke". Chem. Rev., 68 : 153.

Stillman, J. R.; Rosenberg, M. J. and Sachs, P. B. (1986) : "Smoking and reproduction". Fertil. Steril., 46 : 545-566.

Sugano, N. and Ito, K. (2000) : "Nicotine switches the form of H2O2-induced cell death from apoptosis to necrosis in

U937 cells". Immunology Letters, 72 : 163-166.

Suzuki, J.; Bayna, E.; Molle, D. E. and Wilbur, Y. W. and Lew, F. A. (2003) : "Nicotine inhibits cardiac apoptosis induced by lipopolysaccharide in rats". J Am College of Cardiology, 41 : 482-488.

To, W. W. and Tang, M. H. (1999) : "The association between maternal smoking and fetal hydranencephaly". J. Obstet. Gynecol. Res., 25 : 39 - 42.

Vaglenova, J.; Birru, S.; Pandiella, N. M. and Breese, C. R. (2004) : "An assessment of the long - term developmental and behavioral teratogenicity of prenatal nicotine exposure". Be. haw. Brain Res., 2 : 159-70.

Van Der Veen, F. and Fox, H. (1982) : "The effects of cigarette smoking on the human placenta: a light and electron microscopic study". Placenta, 3 : 243-56.

Van Der Velde, W. J.; Peereboom-Stegeman, J. H.; Treffers, P. E. and James, J. (1985) : "Basal lamina thickening in the placentae of smoking mothers". Placenta, 6 : 329-40.

Van Der Velde, W. J.; Copius Peereboom-Stegeman J. H.; Treffers, P. E. and James, J. (1983) : "Structural changes in the placentae of smoking mothers: a quantitative study". Placenta, 4 : 231-40.

Vessey, M.; Baron, J. and Poll, R. (1983) : "Oral contraceptives and breast cancer, final report of an epidemiological study". Br. J. Cancer, 47: 455.

Went, S. W.; Goldenberg, K. L.; Cutter, G. C.; Hoffman, H. J.; liver, S. P.; Davis, R. O. and Dullard, M. B. (1990) : "Smoking, maternal age, fetal growth and gestational age at delivery". Am. J. Obstet. Gynecol., 162 : 53-58.

Wilson, J. G. (1964) : Teratology Principles and Techniques. 10th ed. Chicago Illinois, the University of Chicago Press, P.P. 134-137.

Yildiz, D.; Ercal, N. and Armstrong, W. D. (1998) : "Nicotine enantiomers and oxidative stress". Toxicology, 130 : 155-165.

Zdravkovic, T.; Genbacev, O.; Mc Master, M. T. and Fisher, S. J. (2005) : "The adverse effects of maternal smoking on the human placenta : a review". Placenta, 26 : S81-86.

Zdravkovica, T.; Genbaceva, O.; Prakobphola, A.; Cvetkovicd, M.; Schanza, A.; McMastera, M. and Susan J. Fishera, B. C. (2006) : "Nicotine downregulates the l-selectin system that medi-

ates cytotrophoblast emigration from cell columns and attachment to the uterine wall". Reprod Toxicol., 22 : 69-76.

Zenzes, T. M. (2000) : "Smoking and reproduction: gene damage to human gametes and embryos". Human Reproduction Update, 6 : 122-131.

Zenzes, M. T.; Puy, L. A. and Bielecki, R. (1997) : "Immunodetection of benzo [a]pyrene in spare embryos of women in IVF-ET exposed to cigarette smoke". Fertil. and Steril., 68 : S155-S156.

تأثير إعطاء النيكوتين ثم إنقطاعه على الأعضاء التناسلية والخصوبة فى إناث الجرذان البالغة

المشتركون فى البحث

د. منال محمود سامى **د. رنده حسين عبدالهادى***

د. أمل راتب عبدالسميع **د. هبه محمد سعد الدين****

أقسام التشريح، الطب الشرعى* ، الهستولوچى **

كلية الطب - جامعة أسيوط

توجد علاقة وثيقة بين التدخين ونقص الخصوبة فى الإناث عموماً ولكن تفسير هذه العلاقة لم يتم توضيحها بالكامل بعد. لذلك إهتمت هذه الدراسة بتأثير النيكوتين وانقطاعه أيضاً على بعض الأعضاء التناسلية بالإضافة إلى التغيرات الشكلية فى المواليد لأمهات تمت معالجتها بالنيكوتين.

وقد قسمت الحيوانات إلى مجموعتين أساسيتين : مجموعة (أ) وتشمل الفئران غير الحوامل وقسمت هذه المجموعة إلى ثلاث مجموعات فرعية :

١- المجموعة الضابطة وتم حقنها بمحلول ملحى فقط.

٢- المجموعة التى تم حقنها تحت الجلد بالنيكوتين بجرعة ٤رمجم/كجم من وزن الجسم لمدة ثلاثة أسابيع.

٣- المجموعة التى تم حقنها بالنيكوتين بنفس الجرعة والمدة السابقتين ثم تركت لمدة شهرين بدون علاج.

مجموعة (ب) وتشمل الفئران الحوامل وتم تقسيمها إلى مجموعتين فرعيتين.

(١) المجموعة الضابطة وحقنت بمحلول الملح فقط من اليوم السادس إلى اليوم العشرين من الحمل.

(٢) المجموعة التى حقنت بالنيكوتين بجرعة ٤رمجم/كجم من وزن الجسم من اليوم السادس إلى اليوم العشرين من الحمل.

وعند الإسبوع الثالث أخذت عينات من المبيضين والرحم فى المجموعة (أ) ووجد أن النيكوتين أدى إلى تأخر فى نمو الحويصلات الموجودة فى المبايض وزيادة فى تلك المتهالكة ونقص ملحوظ فى السليمة منها، كما حدث تهالك فى الأجسام الصفراء.

ومع إنقطاع النيكوتين حدث تحسن ملحوظ ولكنه لم يصل إلى المجموعة الضابطة، بالنسبة للرحم فلوحظ نقص فى سمك الطبقة الداخلية والوسطى من جدار الرحم وكذلك الغدد الموجودة فى الطبقة الداخلية وقد حدث تحسن مع إنقطاع النيكوتين ولكنه لم يصل أيضاً إلى المجموعة الضابطة.

بالنسبة للمشيمة فقد حدث تهالك واضح مما أثر على المواليد التى ظهرت صغيرة فى الحجم نسبياً، كما ظهرت تجاعيد فى الجلد، تشوه فى عظام الجمجمة، تقوس فى الظهر، إنكماش فى منطقة العنق والأطراف، بالإضافة إلى حدوث شق فى العمود الفقرى مصحوباً بفتق فى النسيجين

السحائى والمخى وتأخر فى تعظم العمود الفقرى.

واستنتج أن النيكوتين يعمل على تعطيل نمو الحويصلات المبيضية عن طريق زيادة موت الخلايا المبرمج مما يفسر تأثيره السلبى على الخصوبة. أيضاً التهالك الملحوظ فى المشيمة ربما يكون ضمن العوامل المسببة للتشوهات الخلقية فى المواليد المعرضة أمهاتهم للنيكوتين.